

'Extended' restricted kinematic alignment results in decreased residual medial gap tightness among osteoarthritic varus knees during robotic-assisted total knee arthroplasty

From Medicover Hospitals,
Hyderabad, India

Correspondence should be
sent to A. Parameswaran
doctorapurve@gmail.com

Cite this article:
Bone Jt Open 2024;5(8):
628–636.

DOI: 10.1302/2633-1462.
58.BJO-2024-0054.R1

K. K. Eachempati,¹ A. Parameswaran,¹ V. K. Ponnala,¹ A. Sunil,¹ N. P. Sheth²

¹Department of Orthopaedics, Medicover Hospitals, Hyderabad, India

²Penn Orthopaedics at Pennsylvania Hospital, University of Pennsylvania, Philadelphia, Pennsylvania, USA

Aims

The aims of this study were: 1) to describe extended restricted kinematic alignment (E-rKA), a novel alignment strategy during robotic-assisted total knee arthroplasty (RA-TKA); 2) to compare residual medial compartment tightness following virtual surgical planning during RA-TKA using mechanical alignment (MA) and E-rKA, in the same set of osteoarthritic varus knees; 3) to assess the requirement of soft-tissue releases during RA-TKA using E-rKA; and 4) to compare the accuracy of surgical plan execution between knees managed with adjustments in component positioning alone, and those which require additional soft-tissue releases.

Methods

Patients who underwent RA-TKA between January and December 2022 for primary varus osteoarthritis were included. Safe boundaries for E-rKA were defined. Residual medial compartment tightness was compared following virtual surgical planning using E-rKA and MA, in the same set of knees. Soft-tissue releases were documented. Errors in postoperative alignment in relation to planned alignment were compared between patients who did (group A) and did not (group B) require soft-tissue releases.

Results

The use of E-rKA helped restore all knees within the predefined boundaries, with appropriate soft-tissue balancing. E-rKA compared with MA resulted in reduced residual medial tightness following surgical planning, in full extension (2.71 mm (SD 1.66) vs 5.16 mm (SD 3.10), respectively; $p < 0.001$), and 90° of flexion (2.52 mm (SD 1.63) vs 6.27 mm (SD 3.11), respectively; $p < 0.001$). Among the study population, 156 patients (78%) were managed with minor adjustments in component positioning alone, while 44 (22%) required additional soft-tissue releases. The mean errors in postoperative alignment were 0.53 mm and 0.26 mm among patients in group A and group B, respectively ($p = 0.328$).

Conclusion

E-rKA is an effective and reproducible alignment strategy during RA-TKA, permitting a large proportion of patients to be managed without soft-tissue releases. The execution of minor alterations in component positioning within predefined multiplanar boundaries is a better starting point for gap management than soft-tissue releases.

Take home message

- Extended restricted kinematic alignment is an effective and reproducible strategy during robotic-assisted total knee arthroplasty. It follows the basic principles of restricted kinematic alignment, but uses additional boundaries in the sagittal and transverse planes.
- It results in a decrease in coronal gap imbalance compared to mechanical alignment, and has the potential to manage most knees without soft-tissue releases beyond routine surgical exposure.

Introduction

Multiple alignment strategies for total knee arthroplasty (TKA) have been described.¹ Mechanical alignment (MA) targets neutral distal femoral and proximal tibial resection, resulting in an unconstitutional state in most patients, and frequent gap imbalances requiring soft-tissue releases.²⁻⁵ Kinematic alignment (KA) aims to restore constitutional alignment using anatomical rather than mechanical bone resection, and rarely results in gap imbalances requiring soft-tissue releases.⁶⁻⁹ Restricted kinematic alignment (rKA) sets safe boundaries for KA to avoid recreating suboptimal biomechanics, while permitting minor adjustments in component positioning in the coronal plane, consistent with the native knee.² KA and rKA focus on retention of native femoral anatomy, and restoration of physiological lateral compartment laxity.²

With the advent of robotic-assisted systems, calibration of bony resections with real-time quantification of their effect on the gap status has been rendered possible.^{10,11} Robotic-assisted TKA (RA-TKA) enables precise adjustment of component positioning in multiple planes, resulting in increased attention towards alternative alignment strategies. Moreover, RA-TKA offers the potential for precisely implementing established alignment options including MA, KA, and rKA.¹⁰ Additionally, the use of robotic technology expands the scope of conventional rKA through the use of supplemental boundaries in the sagittal and transverse planes, thereby preventing re-creation of outlier anatomy, while achieving enhanced gap balancing and retaining physiological laxity. This led to the development of a novel alignment strategy by the authors: 'extended rKA' (E-rKA).

We hypothesized that the use of E-rKA during RA-TKA would result in improved gap balance when compared with MA in the same set of knees. Consequently, a large proportion of knees could be managed without soft-tissue releases beyond routine surgical exposure. We also hypothesized that minor adjustments in component positioning compared with soft-tissue releases would be a better starting point for achieving gap balance during RA-TKA. The aims of this study were: 1) to describe the technique of E-rKA during RA-TKA; 2) to compare residual medial compartment tightness following virtual surgical planning using MA and E-rKA, in the same set of osteoarthritic varus knees; 3) to assess the requirement of soft-tissue releases during RA-TKA using E-rKA; and 4) to compare the accuracy of surgical plan execution between knees managed with adjustments in component positioning alone, and those which require additional soft-tissue releases.

Methods

Patient selection and preoperative evaluation

Following approval from the Institutional Ethics Committee from Medicover Hospitals, Hyderabad, India, an observational study was conducted. Informed consent was taken from all study participants. A total of 200 patients who underwent RA-TKA between January and December 2022 for primary osteoarthritis with an intra-articular varus deformity were recruited. Demographic data of all patients were collected. Preoperative weightbearing anteroposterior long-leg and full-leg (including knee) lateral radiographs were obtained. The mechanical lateral distal femoral angle (mLDFA), mechanical medial proximal tibial angle (mMPTA), limb alignment defined by the hip-knee-ankle angle (HKAA), and posterior tibial slope (PTS) were assessed using previously described techniques.¹²⁻¹⁴ Knee phenotype was assessed using the CPAK (coronal plane alignment of knee) classification.¹⁵ All surgeries were performed by a single surgeon (KKE) at a high-volume tertiary care hospital (Medicover Hospitals), using the NAVIO 7.0 (Smith & Nephew, UK) image-free robot. All patients received Legion implants (Smith & Nephew). Cruciate-retaining components were used wherever possible, while cruciate-substituting components were used where the posterior cruciate ligament (PCL) had to be sacrificed.

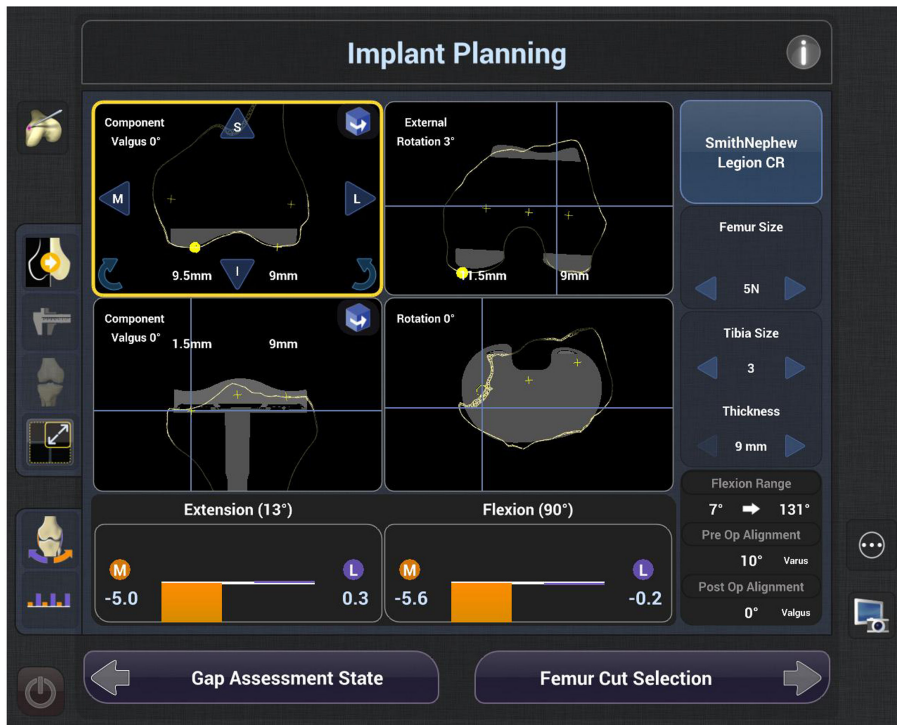
Surgical exposure, and planning of MA

The mid-vastus approach was used for surgical exposure. The anterior capsule and deep fibres of the medial collateral ligament were released. Osteophytes and loose bodies were removed. Bony landmarks and the centres of the hip, knee, and ankle were registered on the robotic system. 3D mapping of the distal femur and proximal tibia was performed, creating a free-collection mesh. The angle between the anatomical transepicondylar axis (aTEA) and the posterior condylar axis (PCA) was assessed on the mesh. The PCA was then used as the reference for setting the desired femoral component rotation (FCR).

The robot planned the distal femoral and proximal tibial resections perpendicular to their respective mechanical axes, at a level based on the manufacturer's recommendation for the specific implant. The smallest femoral component size which would restore posterior condylar offset without causing anterior notching, and the tibial component size which most closely matched the mediolateral dimension of the mesh, were planned. The default values for femoral component flexion (FCF), PTS, and FCR from the PCA were 3° each. Medial and lateral gaps throughout varus- and valgus-stressed range of motion were assessed. The robot presented the 'default plan' and the residual gap status in full extension and 90° of flexion (Figure 1).

The surgeon balanced the lateral compartment, with the aim of creating approximately 0 mm laxity in full extension and 90° of flexion. This was accomplished by altering the distal femoral resection level or femoral component size for isolated extension or flexion gap imbalance respectively, and/or the proximal tibial resection level or the polyethylene insert size for gap imbalance in both extension and flexion. The residual medial compartment tightness remaining to be corrected was noted.

(a)



(b)

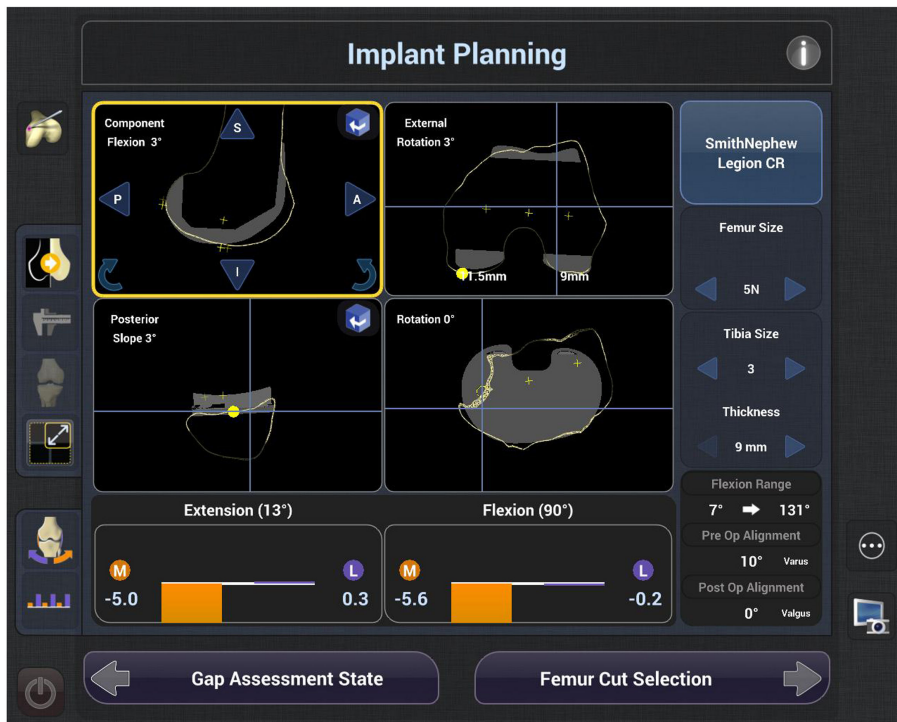


Fig. 1

a) The surgical plan based on mechanical alignment, with the coronal and axial views of the planned femoral and tibial component positioning. b) The surgical plan based on mechanical alignment, with the sagittal and axial views of the planned femoral and tibial component positioning.

Planning and execution of the surgery using E-rKA

The robot permitted 28 types of alterations in the 'default' surgical plan, along 14 degrees of freedom (Table I). The boundaries in Table II were employed. The tibial base-plates used in the study had an asymmetric design, and were

co-aligned with Akagi's line, to ensure optimal coverage. The surgeon focused on retaining native femoral anatomy wherever possible, while performing minor alterations in component positioning within the predefined boundaries on the tibial side, or the femoral side in cases with outlier

Table I. The 28 types of alterations to the default surgical plan, in 14 degrees of freedom permitted by the robot.

Adjustment permitted in component positioning	Femoral component	Tibial component
Displacement along coronal plane	Medial displacement	Medial displacement
	Lateral displacement	Lateral displacement
Displacement along sagittal plane	Superior displacement	Superior displacement
	Inferior displacement	Inferior displacement
Displacement along transverse plane	Anterior displacement	Anterior displacement
	Posterior displacement	Posterior displacement
Rotation in coronal plane	Varus rotation	Varus rotation
	Valgus rotation	Valgus rotation
Rotation in sagittal plane	Flexion	Flexion
	Extension	Extension
Rotation in transverse plane	Internal rotation	Internal rotation
	External rotation	External rotation
Alteration of component size	Increase in size	Increase in size
	Decrease in size	Decrease in size

Table III. A comparison of the gap status following virtual surgical planning during robotic-assisted total knee arthroplasty, using mechanical alignment and extended restricted kinematic alignment.

Compartment (position)	Planned gap status		
	Mean residual gap (MA), mm (SD; range)	Mean residual gap (E-rKA), mm (SD; range)	p-value
Medial (in extension)	-5.16 (3.10; 0.00 to -13.80)	-2.71 (1.66; -0.20 to -7.50)	< 0.001
Medial (in flexion)	-6.27 (3.11; 0.00 to -16.50)	-2.52 (1.63; -0.20 to -9.90)	< 0.001
Lateral (in extension)	0.30 (0.28; 0.00 to 1.00)	0.36 (0.26; 0.00 to 1.00)	< 0.001
Lateral (in flexion)	0.41 (0.27; 0.00 to 1.00)	0.79 (0.14; 0.60 to 1.20)	< 0.001

Negative values indicate tightness, while positive values indicate laxity.
*Paired *t*-test.
E-rKA, extended restricted kinematic alignment; MA, mechanical alignment.

anatomy. The aim was to reduce medial tightness if it was greater than 4 mm, while maintaining lateral laxity of approximately 0 mm and 1 mm in extension and 90° of flexion, respectively.

Based on the authors' preliminary experience with the robot, prebalancing was not performed, as it usually resulted in the need for a thick polyethylene insert. The medial compartment was left up to 4 mm tight, while bony resections were planned to equalize medial gap tightness in extension and flexion. Following excision of the residual portions of the menisci and posterior osteophytes, most patients with a post-planning residual medial tightness up to 4 mm did not require soft-tissue releases for gap balancing. The lateral compartment laxity also increased to a more physiological value of up to 1 mm and 2 mm in extension and flexion, respectively.

Table II. The boundaries used for extended restricted kinematic alignment during robotic-assisted total knee arthroplasty.

Plane	Boundaries
Coronal	mLDFA : 86° to 93°, or 87° to 93°*
	mMPTA : 86° to 93°, or 87° to 93°*
Sagittal	HKAA : 5° varus to 4° valgus, or 4° varus to 3° valgus*
	FCF : 0° to 5° PTS : 2° to 7°
Transverse	FCF + PTS : ≤ 10°
	FCR : 1° external rotation to 5° internal rotation from the aTEA

*Narrower boundaries were used for patients who were aged above 80 years, or had a history of insufficiency fractures or medically treated osteoporosis, to lower the risk of implant subsidence.
FCF, femoral component flexion; FCR, femoral component rotation; HKAA, hip-knee-ankle angle; mLDFA, mechanical lateral distal femoral angle; mMPTA, mechanical medial proximal tibial angle; PTS, posterior tibial slope.

Table IV. Differences in various planned bony resections during robotic-assisted total knee arthroplasty, using mechanical alignment and extended restricted kinematic alignment.

Resection	Mean (MA), mm (SD; range)	Mean (E-rKA), mm (SD; range)	p-value
Distal femur, medial	8.26 (1.33; 4.0 to 10.0)	8.89 (1.67; 5.0 to 14.0)	< 0.001
Distal femur, lateral	8.68 (1.21; 4.0 to 10.0)	9.54 (1.18; 6.0 to 12.0)	< 0.001
Proximal tibia, medial	2.06 (1.97; 0.0 to 7.5)	3.40 (1.86; 0.0 to 8.0)	< 0.001
Proximal tibia, lateral	8.92 (0.45; 8 to 10)	8.95 (0.89; 6.0 to 11.5)	0.663
Posterior femur, medial	11.59 (1.55; 8.0 to 15.0)	10.12 (0.61; 9.5 to 12.5)	< 0.001
Posterior femur, lateral	9.78 (0.93; 7.0 to 13.0)	9.57 (1.53; 6.0 to 15.0)	0.056

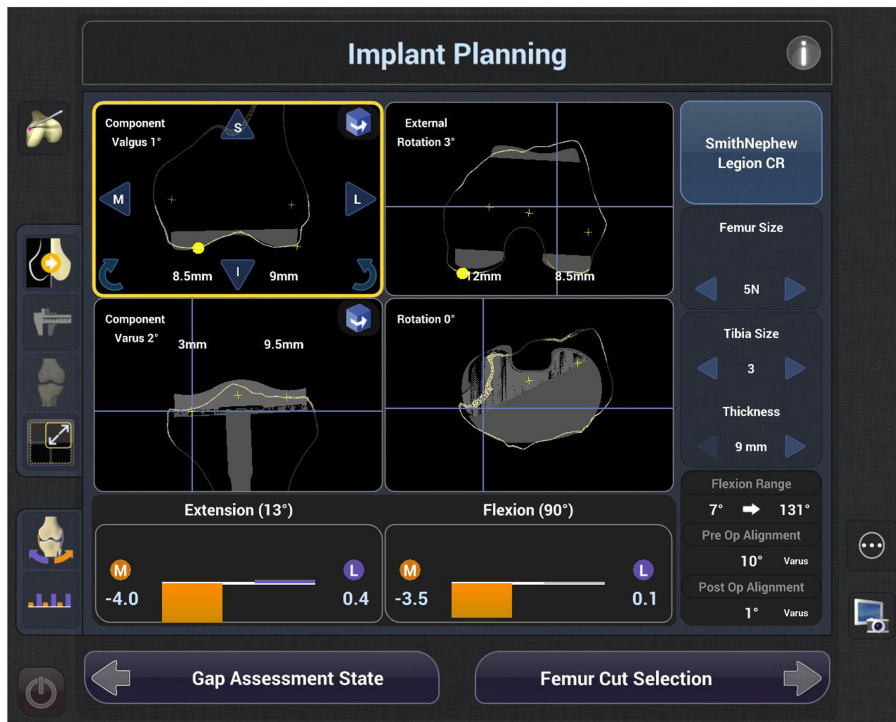
*Paired *t*-test.
E-rKA, extended restricted kinematic alignment; MA, mechanical alignment.

Component size was adjusted where necessary, to match the shape and size of the mesh. Medial tightness in extension or flexion was addressed by altering the coronal angulation of the tibial component in a direction consistent with the native knee, and/or altering the PTS, respectively. Symmetrical tightness in extension and/or flexion was addressed by altering the proximal tibial resection level and/or the PTS, within the predefined boundaries. Bone resection was carried out using the 'all-burr technique'. Postoperative gap status was reviewed with trial components in situ. Where required, soft-tissue releases were performed sequentially. The surgical plans were saved as screenshots in a password-protected robotic system database (Figure 2).

Statistical analysis

Based on a pilot study at the institution, the SD of mean residual medial tightness during RA-TKA was approximately 3 mm. To detect a reduction in medial gap tightness of 1 mm, for a study power of 90% and significance at 0.05, a

(a)



(b)

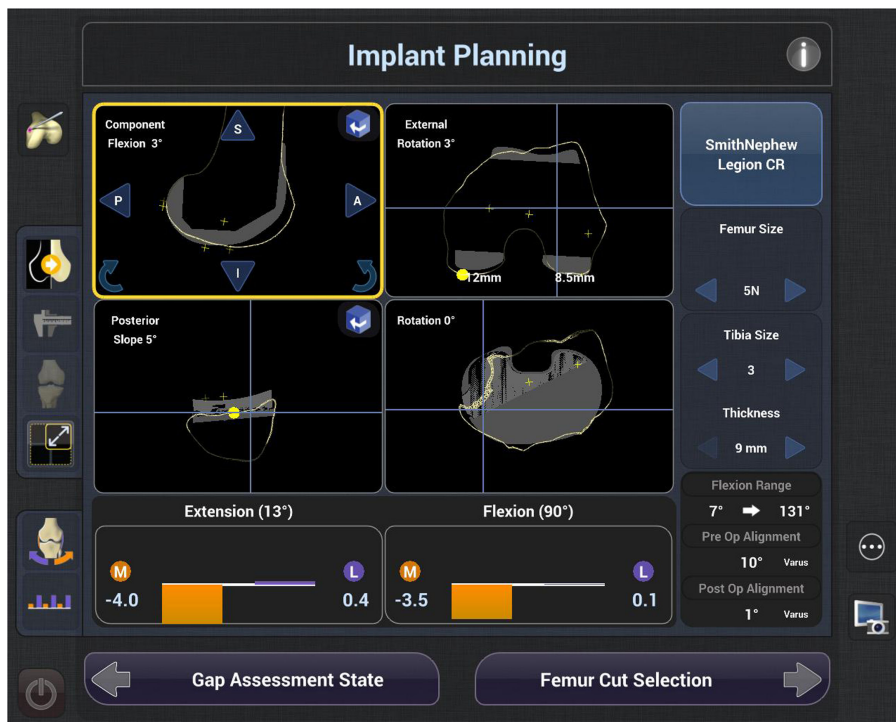


Fig. 2

a) The final surgical plan based on extended restricted kinematic alignment (E-rKA), with the coronal and axial views of the planned femoral and tibial component positioning. b) The final surgical plan based on E-rKA, with the sagittal and axial views of the planned femoral and tibial component positioning.

minimum of 189 samples was required. Statistical analysis was performed using SPSS software version 29 (IBM, USA). Means with SDs were calculated for numerical variables. Proportions of categorical variables were estimated. The Shapiro-Wilk test

was used to assess normality of distribution. Levene's test was used to assess homogeneity of variance. Means of numerical variables were compared using the paired or independent-samples *t*-test, as applicable. Pearson's correlation coefficient

Table V. Preoperative and planned angular parameters using mechanical alignment and extended restricted kinematic alignment, during robotic-assisted total knee arthroplasty.

Angle	Mean preoperative value, ° (SD; range)	Mean planned value using MA, ° (SD; value)	Mean planned value using E-rKA, ° (SD; range)	p-value*
mLDFA	90.27 (2.19; 85 to 95)	90° (0°; fixed value of 90°)	89.43 (1.10; 86 to 93)	< 0.001
mMPTA	83.56 (3.29; 72 to 90)	90° (0°; fixed value of 90°)	87.61 (0.83; 86 to 90)	< 0.001
FCF	-	3° (0°; fixed value of 3°)	2.19 (1.44; 0 to 5)	< 0.001
PTS	11.27 (3.51; 3 to 16)	3° (0°; fixed value of 3°)	4.91 (1.07; 3 to 7)	< 0.001
FCR	-	3° (0°; fixed value of 3°)	0.62 (0.82; 0 to 3)	< 0.001
HKAA	-8.33 (3.28; -18 to -1)	0° (0°, fixed value of 0°)	-1.82 (1.23; -5 to -1)	< 0.001

Negative hip-knee-ankle angle values indicate varus, while positive values indicate valgus.

*Paired *t*-test.

FCF, femoral component flexion; FCR, femoral component rotation; HKAA, hip-knee-ankle angle; mLDFA, mechanical lateral distal femoral angle; mMPTA, mechanical medial proximal tibial angle; PTS, posterior tibial slope.

Table VI. Requirement of soft-tissue releases in the study population.

Soft-tissue release/additional procedures required	Patients, n (%)
None, except routine surgical exposure	156 (78)
Posteromedial corner with or without posterior capsular release	44 (22)
PCL recession	3 (1.5)
PCL release	2 (1.0)
Medial sliding femoral condylar osteotomy	1 (0.5)

PCL, posterior cruciate ligament.

was used to measure linear correlation between numerical variables.

Gap status, bone resection, mLDFA, mMPTA, FCF, PTS, FCR, and HKAA were compared using MA and E-rKA plans. Two subsets of patients who did (group A) or did not (group B) require soft-tissue releases beyond surgical exposure for attaining gap balance were identified, and compared for preoperative HKAA, planned HKAA, postoperative HKAA, planned axis correction ((preoperative HKAA) – (planned HKAA)), and error in postoperative alignment ((postoperative HKAA) – (planned HKAA)). The association between the planned axis correction and errors in postoperative alignment was assessed.

Results

The study population comprised 142 (71%) females and 58 (29%) males; their mean age was 63.1 years (SD 7.91). Among them, 183 patients (91.5%) had an apex-distal knee phenotype, while 17 (8.5%) had an apex-neutral phenotype based on the CPAK classification.¹⁵ A significant reduction in medial gap tightness in extension and flexion was noted when E-rKA was planned in place of MA. A comparison of the gap status following virtual surgical planning using MA and E-rKA is summarized in Table III. The differences in planned bony resection in MA and E-rKA are shown in Table IV. E-rKA, when compared with MA, resulted in decreased posterior femoral resection in the medial compartment, but increased bone

resection from the distal femur and proximal tibia medially, and the distal femur laterally.

Significantly lower values of mLDFA, mMPTA, FCF, and FCR were noted while planning E-rKA, but a higher mean PTS was used (Table V). Overall, 156 patients (78%) were managed without soft-tissue releases beyond routine surgical exposure (Table VI). The required soft-tissue releases among the study participants are outlined in Table VI. Limb alignment was restored within the predefined boundaries in all patients. Table VII demonstrates the differences in alignment-related parameters between patients in groups A and B. No association between planned axis correction and errors in postoperative HKAA was noted (Table VII). There was no evidence of intraoperative femoral notching or patellar maltracking.

Discussion

E-rKA, as described by the authors, represents an evolution of the rKA concept, made possible through the use of robotic-assisted systems. It was found to be a practical and reproducible alignment strategy during RA-TKA, restoring all knees within the predefined boundaries. E-rKA follows the basic principles of rKA, but takes it one step further by setting additional boundaries in the sagittal and transverse planes. It uses KA as a starting point for component positioning and aims to restore physiological lateral laxity, unlike functional alignment, which uses MA as a starting point for surgery with the aim of creating rectangular gaps.¹⁶

The primary finding of this study was that E-rKA compared with MA resulted in reduced residual medial compartment tightness in both extension and flexion during RA-TKA in the same set of osteoarthritic varus knees (Table III). Similar to the findings of Vendittoli et al,² most patients (78%) in the study population were managed using alterations in component positioning alone (Table VI). Soft-tissue releases during TKA unfavourably affect clinical outcomes.¹⁷ The elimination of the need for soft-tissue releases in 78% of the patients would improve their likelihood of achieving optimal clinical outcomes. Given the narrow boundaries of E-rKA, however, preparedness for the requirement of all types of soft-tissue releases would be appropriate. The improvement in gap balance by the use of E-rKA instead of MA is understandable, since a part of the onus of attaining balance is

Table VII. Overall and group-wise alignment related parameters during robotic-assisted total knee arthroplasty.

Parameter	Overall	Group A	Group B	p-value*
Mean preoperative HKAA, ° (SD; range)	-8.33 (3.28; -18 to -2)	-7.93 (3.00; -15 to -2)	-8.44 (3.35; -18 to -2)	0.363
Mean HKAA, planned, E-rKA, ° (SD; range)	-1.82 (0.92; -5 to -1)	-1.80 (0.93; -5 to -1)	-1.83 (0.92; -5 to -1)	
↓	↓	↓	↓	
Mean postoperative HKAA, ° (SD; range)	-2.14° (1.35; -5 to 0) (p = 0.001)‡	-2.33 (1.50; -5 to 0) (p = 0.013)‡	-2.09 (1.31; -5 to 0) (p = 0.009)‡	0.841
Mean planned axis correction, ° (SD; range)	6.51 (2.93; 0 to 15)	6.14 (2.84; 0 to 12)	6.62 (2.96; 0 to 15)	0.340
Mean error in postoperative alignment, ° (SD)	0.32 (1.22)	0.53 (1.25)	0.26 (1.22)	0.328
Association between planned axis correction and error in postoperative HKAA	$r = 0.001$ † (p = 0.986)	$r = 0.153$ † (p = 0.322)	$r = -0.034$ † (p = 0.673)	-

Negative hip-knee-ankle angle values indicate varus, while positive values indicate valgus.

*independent-samples *t*-test.

†Pearson's correlation coefficient.

‡Paired *t*-test.

E-rKA, extended restricted kinematic alignment; HKAA, hip-knee-ankle angle.

transferred from soft-tissue releases to component positioning. Our study demonstrates and quantifies this improvement in the same set of knees, using robotic technology, for the first time.

Another important finding of this study was that a significant difference was noted between planned and achieved alignment among patients in group A, as well as group B (Table VII). Patients in group A had a larger mean error in postoperative alignment. This increased error could be indicative of the unpredictability of the effect of soft-tissue releases on alignment. When compared between the two patient groups, however, the difference in errors did not reach statistical significance due to their high variance and the small number of patients in group A. Manual soft-tissue release is subjective and lacks precision.¹⁸ Over-correction or under-correction of deformities cannot be entirely prevented while performing soft-tissue releases, though accuracy may vary between surgeons. The authors believe that alterations in component positioning within predefined boundaries, rather than performance of soft-tissue releases, would be a better starting point for the correction of residual gap imbalance during TKA.

An association between planned axis correction and errors in postoperative alignment was sought, to explore a potential contributory role of large magnitudes of deformity correction, towards the observed errors. No association was found, however (Table VII). This would indicate that the execution of bony resection, as well as soft-tissue release, is associated with a certain constant error, which could be robot- or surgeon-specific, but is not dependent on the magnitude of deformity correction required. The robotic system is associated with an additional potential error up to 0.5° since it uses rounded off integers to quantify alignment. The sum total of these errors in alignment could exceed 1°. The authors therefore believe that narrowing the boundaries of rKA by 1°, especially where soft-tissue releases are planned, could prevent unacceptable postoperative alignment.

The technique of MA was introduced in an era when surgical instruments lacked precision.¹⁹ Though reproducible, it does not consider the full range of normal knee

anatomy, and focuses on prosthetic survival instead.²⁰ A better understanding of the functional anatomy of the knee led to the introduction of KA and rKA.^{6,21,22} Various wide and narrow coronal plane boundaries have been advocated for rKA;^{2,20,23,24} those described by MacDessi et al¹⁵ were used in our study. Given the potential for alterations in FCF, PTS, and FCR to affect gap balance favourably, and considering the possibility of anatomical outliers in multiplanar angular parameters, the authors used an extended version of conventional rKA, with permitted alterations in the sagittal and transverse planes.^{10,25-27} The boundaries for FCR were set between 1° of external rotation and 5° of internal rotation from the aTEA to match the described rotational boundaries of +/- 3° from the surgical transepicondylar axis (sTEA), since the sTEA lies in approximately 2° of internal rotation from the aTEA but is difficult to define intraoperatively using image-free robotics due to soft-tissue coverage.²⁸

Component positioning with the NAVIO image-free robotic system and its more recent iteration, CORI, is based on the surgically planned mL DFA and mMP TA, and the resulting planned arithmetic HKAA. These are implemented by the robot, based on the femoral and tibial mechanical axes (derived using the principles of computer-assisted navigation, through the registration of bony landmarks and joint centres of the hip, knee, and ankle), and the variance of the planned angles from their respective perpendiculars. The accuracy of this system in component positioning is well-established,²⁹⁻³² and found to be comparable or superior to image-based systems.^{33,34} Its mapping accuracy, though unclear, is relevant merely in the context of shape and size matching of planned components with the free-collection mesh during virtual surgery.

The greatest strength of our study is that the same set of knees was used for comparing the effects of E-rKA and MA, thereby eliminating the probability of errors arising from inherent anatomical differences between different sets of knees, as well as any possibility of bias. This was made possible through the use of robotic technology and virtual surgical planning. RA-TKA permitted adjustments in the sagittal and transverse planes within predefined boundaries, in addition

to described strategies for coronal plane management. The primary limitation of our study also arises from the use of a single set of knees, since the effect of the decreased residual medial gap tightness could not be assessed in terms of the requirement of various soft-tissue releases, or improvements in clinical outcome scores. Another limitation of our study was that pre- and postoperative CT scans were not performed.

E-rKA is an effective and reproducible alignment strategy during TKA, enabled by robotic technology through multiplanar component adjustment possibilities. It is associated with lesser coronal gap imbalance than MA among osteoarthritic varus knees, and has the potential to manage most knees without soft-tissue releases beyond routine surgical exposure. Errors during surgical plan execution could be robot- or surgeon-related, and could occur irrespective of soft-tissue releases. Given the larger error values and the possibility of over- or under-correction of deformities during soft-tissue releases, however, alterations in component positioning within predefined boundaries would be a better starting point for correcting gap imbalance. Further research is required to assess the potential benefits of E-rKA during RA-TKA, in terms of clinical outcomes and the need for soft-tissue releases.

References

1. **Matassi F, Pettinari F, Frascò F, Innocenti M, Civinini R.** Coronal alignment in total knee arthroplasty: a review. *J Orthop Traumatol.* 2023;24(1):24.
2. **Vendittoli PA, Martinov S, Blakeney WG.** Restricted kinematic alignment, the fundamentals, and clinical application. *Front Surg.* 2021; 8:697020.
3. **Insall J, Scott WN, Ranawat CS.** The total condylar knee prosthesis. A report of two hundred and twenty cases. *J Bone Joint Surg Am.* 1979;61-A(2):173–180.
4. **Mercuri JJ, Pepper AM, Werner JA, Vigdorich JM.** Gap balancing, measured resection, and kinematic alignment: how, when, and why? *JBJS Rev.* 2019;7(3):e2.
5. **Sheth NP, Husain A, Nelson CL.** Surgical techniques for total knee arthroplasty: measured resection, gap balancing, and hybrid. *J Am Acad Orthop Surg.* 2017;25(7):499–508.
6. **Howell SM, Kuznik K, Hull ML, Siston RA.** Results of an initial experience with custom-fit positioning total knee arthroplasty in a series of 48 patients. *Orthopedics.* 2008;31(9):857–863.
7. **Giorgino R, Nannini A, Scuttari E, et al.** Analysis of short-term clinical and functional outcomes in patients undergoing total knee arthroplasty with kinematic alignment technique. *J Clin Med.* 2023;12(12):3978.
8. **Rivière C, Vigdorich JM, Vendittoli PA.** Mechanical alignment: the end of an era? *Orthop Traumatol Surg Res.* 2019;105(7):1223–1226.
9. **Hutt JRB, LeBlanc M-A, Massé V, Lavigne M, Vendittoli P-A.** Kinematic TKA using navigation: surgical technique and initial results. *Orthop Traumatol Surg Res.* 2016;102(1):99–104.
10. **Lustig S, Sappey-Marinière E, Fary C, Servien E, Parratte S, Batailler C.** Personalized alignment in total knee arthroplasty: current concepts. *SICOT J.* 2021;7:19.
11. **Selvanathan N, Ayeni FE, Sorial R.** Incidence of soft tissue releases in robotic assisted cementless TKA with mechanical alignment and flexion gap balancing. *Arthroplasty.* 2023;5(1):28.
12. **Bellemans J, Colyn W, Vandenneucker H, Victor J.** The Chitranjan Ranawat award: is neutral mechanical alignment normal for all patients? The concept of constitutional varus. *Clin Orthop Relat Res.* 2012;470(1): 45–53.
13. **Marques Luís N, Varatojo R.** Radiological assessment of lower limb alignment. *EFORT Open Rev.* 2021;6(6):487–494.
14. **Cullu E, Aydoğdu S, Alparslan B, Sur H.** Tibial slope changes following dome-type high tibial osteotomy. *Knee Surg Sports Traumatol Arthrosc.* 2005;13(1):38–43.
15. **MacDessi SJ, Griffiths-Jones W, Harris IA, Bellemans J, Chen DB.** Coronal Plane Alignment of the Knee (CPAK) classification. *Bone Joint J.* 2021;103-B(2):329–337.
16. **Kayani B, Konan S, Tahmassebi J, Oussedik S, Moriarty PD, Haddad FS.** A prospective double-blinded randomised control trial comparing robotic arm-assisted functionally aligned total knee arthroplasty versus robotic arm-assisted mechanically aligned total knee arthroplasty. *Trials.* 2020;21(1):194.
17. **Vigdorich JM, Wakelin EA, Koenig JA, et al.** Impact of component alignment and soft tissue release on 2-year outcomes in total knee arthroplasty. *J Arthroplasty.* 2022;37(10):2035–2040.
18. **Plaskos C, Wakelin E, Shalhoub S, et al.** Soft-tissue release rates in robotic-assisted gap-balancing and measured-resection total knee arthroplasty. *Orthop Procs.* 2020;102-B(suppl_2):1.
19. **Vendittoli PA, Blakeney W.** Redefining knee replacement. *Orthop Traumatol Surg Res.* 2017;103(7):977–979.
20. **Almaawi AM, Hutt JRB, Masse V, Lavigne M, Vendittoli PA.** The impact of mechanical and restricted kinematic alignment on knee anatomy in total knee arthroplasty. *J Arthroplasty.* 2017;32(7):2133–2140.
21. **Victor JMK, Bassens D, Bellemans J, Gürsu S, Dhollander AAM, Verdonk PCM.** Constitutional varus does not affect joint line orientation in the coronal plane. *Clin Orthop Relat Res.* 2014;472(1):98–104.
22. **Hutt J, Massé V, Lavigne M, Vendittoli PA.** Functional joint line obliquity after kinematic total knee arthroplasty. *Int Orthop.* 2016;40(1): 29–34.
23. **MacDessi SJ, Griffiths-Jones W, Chen DB, et al.** Restoring the constitutional alignment with a restrictive kinematic protocol improves quantitative soft-tissue balance in total knee arthroplasty: a randomized controlled trial. *Bone Joint J.* 2020;102-B(1):117–124.
24. **McEwen PJ, Dlaska CE, Jovanovic IA, Doma K, Brandon BJ.** Computer-assisted kinematic and mechanical axis total knee arthroplasty: a prospective randomized controlled trial of bilateral simultaneous surgery. *J Arthroplasty.* 2020;35(2):443–450.
25. **Tsukeoka T, Lee TH.** Sagittal flexion of the femoral component affects flexion gap and sizing in total knee arthroplasty. *J Arthroplasty.* 2012; 27(6):1094–1099.
26. **Chon JG, Sun DH, Jung JY, Kim TI, Jang SW.** Rotational alignment of femoral component for minimal medial collateral ligament release in total knee arthroplasty. *Knee Surg Relat Res.* 2011;23(3):153–158.
27. **Okazaki K, Tashiro Y, Mizu-uchi H, Hamai S, Doi T, Iwamoto Y.** Influence of the posterior tibial slope on the flexion gap in total knee arthroplasty. *Knee.* 2014;21(4):806–809.
28. **Victor J.** Rotational alignment of the distal femur: a literature review. *Orthop Traumatol Surg Res.* 2009;95(5):365–372.
29. **Vaidya N, Jaysingani TN, Panjwani T, Patil R, Deshpande A, Kesarkar A.** Assessment of accuracy of an imageless hand-held robotic-assisted system in component positioning in total knee replacement: a prospective study. *J Robot Surg.* 2022;16(2):361–367.
30. **Laddha M, Gaurav S.** Assessment of limb alignment and component placement after all burr robotic-assisted TKA. *Indian J Orthop.* 2021; 55(Suppl 1):69–75.
31. **Collins K, Agius PA, Fraval A, Petterwood J.** Initial experience with the NAVIO robotic-assisted total knee replacement-coronal alignment accuracy and the learning curve. *J Knee Surg.* 2022;35(12):1295–1300.
32. **Laddha MS, Gowtam SV, Jain P.** Accuracy of femoral component external rotation with all burr robotic-assisted total knee arthroplasty. *Malays Orthop J.* 2024;18(1):19–25.
33. **Yee DK, Ng JP, Lau CT, et al.** Surgical accuracy of image-free versus image-based robotic-assisted total knee arthroplasty. *Int J Med Robot.* 2024;20(1):e2574.
34. **Hasegawa M, Tone S, Naito Y, Sudo A.** Comparison of accuracy and early outcomes in robotic total knee arthroplasty using NAVIO and ROSA. *Sci Rep.* 2024;14(1):3192.

Author information

K. K. Eachempati, MS, Consultant and Director

A. Parameswaran, MS, Consultant

V. K. Ponnala, DNB, Consultant

A. Sunil, MS, Consultant and Director

Department of Orthopaedics, Medicover Hospitals, Hyderabad, India.

N. P. Sheth, MD, FACS, Chief of Orthopaedic surgery, Penn Orthopaedics at Pennsylvania Hospital, University of Pennsylvania, Philadelphia, Pennsylvania, USA.

Author contributions

K. K. Eachempati: Conceptualization, Data curation, Methodology, Resources, Supervision, Validation, Visualization, Writing – original draft, Writing – review & editing.

A. Parameswaran: Conceptualization, Data curation, Formal analysis, Investigation, Methodology, Project administration, Resources, Software, Validation, Visualization, Writing – original draft, Writing – review & editing.

V. K. Ponnala: Data curation, Methodology, Validation, Writing – original draft, Writing – review & editing.

A. Sunil: Data curation, Methodology, Validation, Writing – original draft, Writing – review & editing.

N. P. Sheth: Data curation, Methodology, Validation, Writing – original draft, Writing – review & editing.

Funding statement

The authors received no financial or material support for the research, authorship, and/or publication of this article.

ICMJE COI statement

K. K. Eachempati is a consultant for Smith & Nephew, and Biorad Medisys; neither position influenced this study. **N. P. Sheth** is a consultant for Smith & Nephew, Zimmer Biomet, and Medacta; a board member of OrthoInfo and AAOS Now; and member at large of Eastern Orthopaedic Society, all of which also had no influence on this study.

Data sharing

The datasets generated and analyzed in the current study are not publicly available due to data protection regulations. Access to data is limited to the researchers who have obtained permission for data processing. Further inquiries can be made to the corresponding author.

Ethical review statement

This study received prior approval from the Institutional Ethics Committee, Medicover Hospitals (ID: EC/NEW/INST/2022/3132).

Open access funding

The authors report that the open access funding for this manuscript was self-funded.

© 2024 Eachempati et al. This article is distributed under the terms of the Creative Commons Attributions (CC BY 4.0) licence (<https://creativecommons.org/licenses/by/4.0/>), which permits unrestricted use, distribution, and reproduction in any medium or format, provided the original author and source are credited.